ПРИЛОЗИ, Одд. мед. науки, XXXV 3, 2014
CONTRIBUTIONS. Sec. Med. Sci., XXXV 3, 2014

МАНУ
MASA

ISSN 1857-9345
UDC: 616.311-002.2-097

ROLE OF HUMORAL MECHANISMS IN ETIOLOGY OF LICHEN PLANUS

Mirjana Popovska[1], Ladislava Grchevska[2], Aneta Atanasovska-Stojanovska[1], Biljana Kapushevska[3], Ilijana Muratovska [4], Ana Minovska[5], Vera Radojkova-Nikolovska[1], Kristina Mitik[1]

[1] St. Pantelejmon Dental Clinical Centre, Periodontology Clinic, Faculty of Dentistry, Skopje, R. Macedonia
[2] University Department of Nephrology, Skopje, R. Macedonia
[3] St. Pantelejmon Dental Clinical Centre, Prosthodontics Clinic, Faculty of Dentistry, Skopje, R. Macedonia
[4] St. Pantelejmon Dental Clinical Centre, Restorative and Adhesive Dentistry Clinic, Faculty of Dentistry, Skopje, R. Macedonia
[5] University of Medicine, Department of dentistry, Stip, R. Macedonia

Corresponding Author: Popovska Mirjana, Prof. PhD, St. Pantelejmon Dental Clinical Centre Periodontology Clinic, Faculty of Dentistry, Skopje 1000, R. Macedonia, Tel. +389 (0)2 70 51 93 04, E-mail: popovskam2002@yahoo.com

Abstract

Aim: To examine the role of IgA, CIC and component C3 as indicators of humoral immune response in the etiopathogenesis of oral erosive lichen planus (OELP).

Material and method: The study comprised 19 patients with OELP whose samples of blood, saliva and tissue were obtained after carefully taken medical history and clinical examination. Samples of oral mucosa were taken from the site of lesion, i.e. exclusively from buccal mucosa (1 cm in width and length), and from the deep epithelium as well as a segment from the lamina propria. Determination of immunoglobulins in serum and saliva, and determination of component C3, was done using the micro-elisa technique by Rook&Cameron, Engvall and Ulman. Determination of CIC in serum and mixed saliva was done with the PEG (polyethylene glycol) method. Determination of immunoglobulin A and component C3 in biopsy material was done with direct immunofluorescence.

Results: Levels of immunoglobulin A in serum in OELP during exacerbation were decreased (1.04 ± 0.49 gr/l) and during remission increased (5.92 ± 0.62) in comparison with the control group ($p < 0.001$). Levels of CIC during exacerbation and remission were increased ($p < 0.001$), and component C3 levels were increased in both examined phases in the examined group compared with the control group ($p < 0.05$). Deposits of IgA were registered in one (5.88%) patient with OELP and component C3 was registered in 3 (17.64%) patients.

Conclusion: Changes in IgA values, as well as CIC and component C3, may correlate with changes in oral mucosa emphasizing the role of humoral immune response in the pathogenesis of oral lichen planus.

Key words: erosive lichen planus, humoral immunity, immunoglobulin A, CIC, component C3.

Introduction

The etiology of lichen planus is still not well established, but it has been confirmed that different causes participate in its pathogenesis [1, 2]. It is believed that immunologic mechanisms are involved as one of the potential factors in the pathogenesis of this common disease [1–3].

The immunological ground is one of the priority mechanisms in the multicausal pathogenesis of oral lichen planus in which immunoglobulins [4, 5] and autoantibodies [6–9] play the key roles. Literature reports related to this issue differ. Some studies have presented increased [4, 5, 8, 10, 11], reduced [11, 12] or



ACTA STOMATOLOGICA NAISSI

Previous issues

Indexing

Subscribe

Contact ASN

Members of ASN

Editorial Code and Statement

Instructions for Authors and Contributors

Submission Checklist

Indexed in online library:

EBSCO - http://search.ebsco.com
DOAJ - www.doaj.org
SCOPUS & EMcare - www.elsevier.com
www.info.scopus.com
ASN ELSEVIER SCOPUS & EM CARE

Acta Stomatologica Naissi is the official Journal of the University of Nis, Faculty of Medicine and Clinic of Stomatology in Nis. It was founded in 1984 to provide the dental community with current and scientifically grounded information on research, education as well as patient care in dentistry.

The Journal is financially supported by: (decision # 451-03-2489/2002-02; 451-03-330/2003-02; 451-03-884/2004-02; 451-03-4180/2005-02;451-03-286/2009/2010-02/1 Faculty of Medicine and Clinic of Dentistry Nis.

The Journal is published twice a year. Subscription for 2011 is for individuals 50€, and for institutions 100€. For detailes of payment contact: e-mail: tijanicm@yahoo.com. Subscription for 2011 is for individuals 5000 RSD, and for institutions 10000 RSD account 840-591-667-33 Klinika za stomatologiju Nis.

Journal is published twice a year.

Editor In Chief: Nikola Burić
Assistant Editor In Chief: Slavoljub Šurdilović † (1941 – 2010)

Editorial Board

Dragan Krasić
Mirjana Janošević
Draginja Kojović
Ljiljana Kesić
Zorica Ajduković
Larisa Blažić

Ljubomir Todorović
Aleksandar Igić
Goran Jovanović
Dragica Dačić-Simonović
Milanka Savić
Danimir Jevremović

Marjan Marjanović
Nevenka Teodorović
Jovanka Gašić
Milan Zeljković
Nebojša Krunić

International Consultants

Professor Dr. Dr. J. Reuther, Würzburg, Germany
Professor Dr. Dr. Josip Bill, Würzburg, Germany
Professor Dr. Richard D. Bebermeyer, Houston, USA
Professor Dr. Ulf Nannmark, Göteborg, Sweden
Professor Dr. Dr. Joachim Mühling, Heidelberg, Germany
Professor Dr. Kazuki Hasegawa, Shizuoka, City, Japan
Professor Dr. Ludovico Sbordone, Pisa, Italy
Professor Dr. Ioannis Papadogianis, Thessaloniki, Greece
Professor Dr. Antoan Steas, Thesaloniki, Greece
Professor Dr. Todor Peev, Sofia, Bulgaria
Professor Dr. Sc. Dr. Rade Paravina, Houston, USA
Professor Dr. Sc. Dr. Joe Ontiveros, Houston, USA
Prof. dr Ivana Čuković-Bagić, Zagreb, Croatia
Prof. dr Željko Verzak, Zagreb, Croatia
Dr. Sc. Dr. Sofia Tranæus, Huddinge, Sweden
Dr. Sc. Dr. Goran Stanisavljević, Vancouver, Canada

Secretaries

Saša Stanković e-mail adress: petras@open.telekom.rs
Miloš Tijanić e-mail adress: tijanicm@yahoo.com
Marija Igić e-mail adress: igicm@medfak.ni.ac.rs

Primljen/ Received on : 02.06.2015.
Revidiran/ Revised on : 04.09.2015.
Prihvaćen/ Accepted on : 28.09.2015.

KLINIČKI RAD
CLINICAL ARTICLE
doi:10.5937/asn1572493P

PROMENE PLJUVAČKE KOD OSOBA SA BULOZNIM LIHEN PLANUSOM

SALIVARY HUMORAL CHANGES IN ORAL BULLOUS LICHEN PLANUS

Mirjana Popovska[1], Ana Minovska[2], Vera Radojkova-Nikolovska[1], Ilijana Muratovska[1], Biljana Kapuševska[1], Pavlina Aleksova[1], Spiro Spasovski[3]

[1]UNIVERZITET SV. ĆIRILA I METODIJA, STOMATOLOŠKI FAKULTET, 1000 SKOPJE, REPUBLIKA MAKEDONIJA
[2]UNIVERZITET GOCE DELČEV, MEDICINSKI FAKULTET, 1000 ŠTIP, REPUBLIKA MAKEDONIJA
[3]PRIVATNA STOMATOLOŠKA ORDINACIJA „FJOLLA MEDIKA", 1000 SKOPJE, REPUBLIKA MAKEDONIJA

[1]UNIVERSITY ST. CYRIL AND METHODIUS, FACULTY OF DENTISTRY, 1000 SKOPJE, REPUBLIC OF MACEDONIA
[2]UNIVERSITYGOCEDELČEV, FACULTY OF MEDICINE, 1000 ŠTIP, REPUBLIC OF MACEDONIA
[3]PRIVATE DENTAL OFFICE „FJOLLAMEDIKA", 1000 SKOPJE, REPUBLIC OF MACEDONIA

Sažetak

Cilj: *Cilj istraživanja bio je ispitivanje humoralnih mehanizama u pljuvački kod pacijenata sa buloznim lihen planusom u fazi egzacerbacije i remisije.*
Materijal i metod: *Praćeno je devetnaest pacijenata sa oralnim buloznim lihen planusom. Pljuvačka je prikupljana u jutarnjim časovima, bez stimulacije, u količini 5-10 cm³. Određivanje imunoglobulina, C_3 i C_4 u pljuvački vršilo se primenom tehnike „microelis". Cirkulišući imuni kompleksi u serumu i pljuvački određivani su PEG metodom. Dobijeni rezultati upoređivani su sa kontrolnom grupom i međusobno u fazi egzacerbacije i remisije. Rezultati su statistički obrađeni Studentovim „t" - testom.*
Rezultati: *Ispitivanja su pokazala da je količina IgA u pljuvački značajno smanjena , dok je količina IgG i IgM značajno uvećana. Vrednosti imunoglobulina A, G i M u fazi remisije značajno su povećane kod bolesnika u odnosu na kontrolnu grupu. Upoređivanjem pljuvačke u fazi egzacerbacije i remisije dobile su iste količine IgG u oba stadijumima bolesti , ali evidentno povišene vrednosti IgA i malo značajno povećanje vrednosti IgM. U kontrolnoj grupi i grupi pacijenata u fazi egzacerbacije i remisije takođe su povećane CIC vrednosti . Podaci ukazuju na visoko značajnu depresiju komponente C3 u fazi egzacerbacije, dok je u remisiji vidljivo malo značajno smanjenje. Komplement komponente C4 u fazi remisije opada u poređenju sa kontrolnom grupom.*
Zaključak: *Postoji evidentno učešće pojedinih komponenti pljuvačke u patogenezi oralnog lihen planusa, ali konačna pozicija za prevlast humoralnih mehanizama u patogenezi buloznog lihen planusa još uvek ne postoji.*

Ključne riječi: bulozni oralni lihen planus, pljuvačka, imunoglobulini, komplement

Address for correspondence:
Mirjana Popovska , Prof. PhD,
University St. Cyril and Methodius, Faculty of dentistry,
MajkaTereza bb, 1000 Skopje, Republic of Macedonia,
E-mail: popovskam2002@yahoo.com
Tel:+38970519304

Abstract

Background: *To investigate the salivary humoral mechanisms in patients with bullous lichen planus, in the phases of exacerbation and remission.*
Material and Method: *Nineteen patients with bullous oral lichen planus were followed. Saliva was collected in the morning without stimulation in the amount from 5-10 cm³. The determination of immunoglobulins, C_3 and C_4 in the saliva was performed using the micro-ELISA technique. The circulating immune complexes in the serum and saliva were determined by the PEG method. The results were compared with a control group and within the group in the phases of exacerbation and remission. The results were statistically processed by Student's t - test .*
Results: *Salivary IgA showed a significant decrease, whereas IgG and IgM significantly increased. The values of immunoglobulin A, G and M in the phase of remission were significantly increased compared with the control group.*
By comparing salivary immunoglobulins in the phases of exacerbation and remission, identical amounts of IgG in both stages of the disease were observed. However, considerably elevated values of IgA and slightly significant increase in the values of IgM were noted. CIC values in the control group and in patients' group in the phases of exacerbation and remission were increased. Data suggest a highly significant depression of C_3 component in the exacerbation phase, while in remission a slightly significant decrease was evident. Complement component C_4 in the remission phase compared with a control group was declined.
Conclusion: *There is an evident involvement of certain saliva components in the pathogenesis of oral lichen planus, but the final predominance of humoral mechanisms in the pathogenesis of bullous lichen planus does not exist yet.*

Key words: bullous oral lichen planus, salivary immunoglobulins, complement.

© 2015 Faculty of Medicine in Niš. Clinic of Dentistry in Niš. All rights reserved / © 2015. Medicinski fakultet Niš. Klinika za stomatologiju Niš. Sva prava zadržana.

ID DESIGN PRESS
OPEN ACCESS MACEDONIAN JOURNAL OF MEDICAL SCIENCES [formerly known as Macedonian Journal of Medical Sciences] eISSN 1857-9

POPULAR ARTICLES

»Current Scientific Impact of Ss Cyril and Methodius University of Skopje, Republic of Macedonia in the Scopus Database (1960-2014)
2148 views since: 2015-01-25

»Gastrointestinal Colonization with Vancomycin-Resistant Enterococci in Hospitalized and Outpatients
1969 views since: 2015-10-27

»Molecular Diagnosis of Toxoplasmosis in Non Immune Pregnant Females
1288 views since: 2014-09-15

»Ethanolic Extract of Emilia sonchifolia Leaves Possess Erythropoietic and Hepatoprotective Effect in Mice Infected with Plasmodium Berghei Berghei
1208 views since: 2014-03-15

»Sleep Organisation in Depression and Schizophrenia: Index of Endogenous Periodicity of Sleep as a State Marker [Retracted]
1176 views since: 2013-12-15

»Use of Medicines from the Group of Benzodiazepines in the Period of 2003-2013 Year in the Republic of Macedonia
1049 views since: 2014-12-24

»Autism and Fragile X: Is There a Neurochemical Link?
989 views since: 2014-12-15

»Effect of Newly Synthesized Polypropylene/Silver Nonwoven Fabric Dressing on Incisional Wound Healing in Rats
937 views since: 2014-09-15

»Risk Factors for Relapse and Mortality of Clostridium Difficile-Associated Diarrhea
675 views since: 2014-05-12

»Is Neck Circumference an Indicator for Metabolic Complication of Childhood Obesity?
603 views since:

Open Access Macedonian Journal of Medical Sciences

Open Access Macedonian Journal of Medical Sciences (OAMJMS) [formerly known as Macedonian Journal of Medical Sciences] is a top-tier open access medical science journal published by the ID Design 2012/DOOEL Skopje, Naroden Front No. 13/45, 1000 Skopje, Republic of Macedonia. OAMJMS is an international, modern, general medical journal covering all areas in the medical sciences, from basic studies to large clinical trials and cost-effectiveness analyses. We publish mostly human studies that substantially enhance our understanding of disease epidemiology, etiology, and physiology; the development of prognostic and diagnostic technologies; trials that test the efficacy of specific interventions and those that compare different treatments; and systematic reviews. We aim to promote translation of basic research into clinical investigation, and of clinical evidence into practice. We publish occasional studies in animal models when they report outstanding research findings that are highly clinically relevant. Our audience is the international medical community as well as educators, policy makers, patient advocacy groups, and interested members of the public around the world. OAMJMS is published quarterly online version.

The Open Access Macedonian Journal of Medical Sciences (OAMJMS) publishes Medical Informatics, Basic Science, Clinical Science, Case Report, Brief Communication, Public Health, Public Policy, and Review Article from all fields of medicine and related fields.

This journal also publishes, continuously or occasionally, the bibliographies of the members of the Society, medical history, medical publications, thesis abstracts, book reviews, reports on meetings, information on future meetings, important events and dates, and various headings which contribute to the development of the corresponding scientific field.

Indexing

Academic Journals Database, Bielefeld Academic Search Engine (BASE), CAB Direct (Login Required), Chemical Abstract Service (CAS), CiteFactor, CNKI Scholar, CNP Linker, COnnecting REpositories (CORE), De Gruyter, DeepDyve, Directory of Open Access scholarly Resources (ROAD), Directory of Research Journals Indexing (DRJI), EBSCO (Central & Eastern European Academic Source) (Login Required), EMBASE (Login Required), Global Health database (Login Required), Global Impact Factor (GIF), Google Scholar, HINARI Access to Research Initiative, Index Copernicus, InnoSpace Scientific Journal Impact Factor (SJIF), International Impact Factor Services (IIFS), JIFACTOR, JournalTOCs, Open Academic Journals Index (OAJI), Open Access Library (OALib), OVID EMBASE (Login Required), SCImago Journal & Country Rank (SJR), SciRew, Scopus (Login Required), Source Normalized Impact per Paper (SNIP), SouthEast European Science Advanced through Evaluation (SEESAmE), Summon™ Service (Login Required), The Knowledge Network, The Cochrane Library: Cochrane Database of Systematic Reviews, Universal Impact Factor, Wanfang Data, WorldCat.

Announcements

No announcements have been published.

More Announcements...

2016: OnlineFirst (OAMJMS)

OA Maced J Med Sci electronic publication ahead of print,
published on January 29, 2016 as http://dx.doi.org/10.3889/oamjms.2016.026

ID Design 2012/DOOEL Skopje
Open Access Macedonian Journal of Medical Sciences.
http://dx.doi.org/10.3889/oamjms.2016.026
eISSN: 1857-9655
Stomatology

The Effects of NBF Gingival Gel Application in the Treatment of the Erosive Lichen Planus: Case Report

Mirjana Popovska[1*], Jasmin Fidovski[2], Sonja Mindova[1], Katerina Dirjanska[1], Stevica Ristoska[1], Emilija Stefanovska[1], Vera Radojkova-Nikolovska[1], Kristina Mitic[1], Biljana Rusevska[1]

[1]Faculty of Dentistry, Ss. Cyril and Methodius University of Skopje, 1000 Skopje, Republic of Macedonia; [2]PHO „Fjolla Medika", Skopje, Republic of Macedonia

Citation: Popovska M, Fidovski J, Mindova S, Dirjanska K, Ristoska S, Stefanovska E, Radojkova-Nikolovska V, Mitic K, Rusevska B. The Effects of NBF Gingival Gel Application in the Treatment of the Erosive Lichen Planus: Case Report. OA Maced J Med Sci. http://dx.doi.org/10.3889/oamjms.2016.026

Key words: erosive lichen planus; therapy; topical treatment; NBF gingival gel.

***Correspondence:** Mirjana Popovska, Prof, PhD. Faculty of Dentistry, Ss. Cyril and Methodius University of Skopje, 1000 Skopje, Republic of Macedonia. Tel: +38970519304. E-mail: popovskam2002@yahoo.com

Received: 31-Oct-2015; **Revised:** 24-Jan-2016; **Accepted:** 25-Jan-2016; **Online first:** 29-Jan-2016

Copyright: © 2016 Mirjana Popovska, Jasmin Fidovski, Sonja Mindova, Katerina Dirjanska, Stevica Ristoska, Emilija Stefanovska, Vera Radojkova-Nikolovska, Kristina Mitic, Biljana Rusevska. This is an open access article distributed under the terms of the Creative Commons Attribution License, which permits unrestricted use, distribution, and reproduction in any medium, provided the original author and source are credited.

Competing Interests: The authors have declared that no competing interests exist.

Abstract

The therapy of erosive lichen planus (ELP) has been particular problem in the treatment of oral lesions. This case of ELP in male patient 29 years old was treated with topic application of the NBF gingival gel, three times a day after meal, previously rinsed with Clorhexidine gluconate 0.12%. After 5 days of treatment, initial improvements were recorded, and after two weeks of application of the NBF gingival gel we observed significant improvement. Clinical monitoring after the fifth day showed mild epithelialization of the eroded mucosa, yet still present erythematous base of the lesion. After the second week the erythema area was significantly reduced and the eroded surfaces of the mucosa were minimal, measured less than 0.5 mm. After the third week there were no erosions to detect on the oral mucosa, yet still present vague redness, which completely pulled after the fourth week. Treatment ended after the fifth week when the topical application of the NBF gingival gel was terminated, and therapy was done, and clinically achieved effects remained stable even after the third month of the treatment. Topic application of the NBF gingival gel with ELP patients showed positive clinical effects in relatively short time period.

Introduction

Oral lichen planus (OLP) is a chronic disease, with unknown etiology, where the autoimmune mechanisms take a particular place. It is believed that the increased production on free radicals (ROS), may play an important role in the pathogenesis of various skin diseases, such as atopic dermatitis, psoriasis, vitiligo [1], and lichen planus, where the presence of oxidative stress is recently been proved [2]. Actually, the oxidative stress is caused between theimbalance in production of reactive free radicals (ROS) and the organism's ability to neutralize reactive intermediaries, which are the consequence of the caused impairment [3]. Created lesions with potentially-present comparative DNA, result of the oxidative stress, can contribute to the development of the malignancy in the oropharyngeal area [4, 5]. It happens at lichen planus atrophic, bullous and erosive type, but usually, not at reticular type.

If we are called on the present oxidative stress, it is completely logical, that the disease will be treated with topical antioxidants, which on some level are our therapeutic experience.

Although the findings suggest that corticosteroids are the number one cure of ELP even when they are applied topically, though it is likely that certain patients can not apply them because of the numerous long-term effects. From this follows the

PRESS

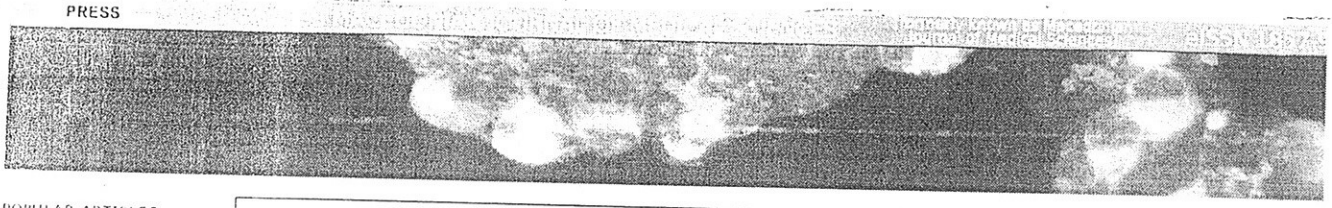

POPULAR ARTICLES

»Current Scientific Impact of Ss Cyril and Methodius University of Skopje, Republic of Macedonia in the Scopus Database (1960-2014)
1595 views since: 2015-01-25

»Gastrointestinal Colonization with Vancomycin-Resistant Enterococci in Hospitalized and Outpatients
1514 views since: 2015-10-27

»Molecular Diagnosis of Toxoplasmosis in Non Immune Pregnant Females
1024 views since: 2014-09-15

»Sleep Organisation in Depression and Schizophrenia: Index of Endogenous Periodicity of Sleep as a State Marker [Retracted]
881 views since: 2013-12-15

»Ethanolic Extract of Emilia sonchifolia Leaves Possess Erythropoietic and Hepatoprotective Effect in Mice Infected with Plasmodium Berghei Berghei
810 views since: 2014-03-15

»Use of Medicines from the Group of Benzodiazepines in the Period of 2003-2013 Year in the Republic of Macedonia
799 views since: 2014-12-24

»Combination of Left Ventricular Noncompaction and Bicuspid Aortic Valve in 19-Year-Old Male: A Case Report from Republic of Macedonia
765 views since: 2013-02-14

»Autism and Fragile X: Is There a Hemochemical Link?
742 views since: 2014-12-15

»Effect of Newly Synthesized Polypropylene/Silver Nonwoven Fabric Dressing on Incisional Wound Healing in Rats
693 views since: 2014-09-15

»Risk Factors for Relapse and Mortality of Clostridium Difficile-Associated Diarrhea
519 views since: 2014-05-12

Home > 2016

Open Access Macedonian Journal of Medical Sciences

Open Access Macedonian Journal of Medical Sciences (OAMJMS) [formerly known as Macedonian Journal of Medical Sciences] is a top-tier open access medical science journal published by the ID Design 2012/DOOEL Skopje. Naroden Front No. 13/45, 1000 Skopje, Republic of Macedonia. OAMJMS is an international, modern, general medical journal covering all areas in the medical sciences, from basic studies to large clinical trials and cost-effectiveness analyses. We publish mostly human studies that substantially enhance our understanding of disease epidemiology, etiology, and physiology; the development of prognostic and diagnostic technologies; trials that test the efficacy of specific interventions and those that compare different treatments; and systematic reviews. We aim to promote translation of basic research into clinical investigation, and of clinical evidence into practice. We publish occasional studies in animal models when they report outstanding research findings that are highly clinically relevant. Our audience is the international medical community as well as educators, policy makers, patient advocacy groups, and interested members of the public around the world. OAMJMS is published quarterly online version.

The Open Access Macedonian Journal of Medical Sciences (OAMJMS) publishes Medical Informatics, Basic Science, Clinical Science, Case Report, Brief Communication, Public Health, Public Policy, and Review Article from all fields of medicine and related fields.

This journal also publishes, continuously or occasionally, the bibliographies of the members of the Society, medical history, medical publications, thesis abstracts, book reviews, reports on meetings, information on future meetings, important events and dates, and various headings which contribute to the development of the corresponding scientific field.

Academic Journals Database, Bielefeld Academic Search Engine (BASE), CAB Direct (Login Required), Chemical Abstract Service (CAS), CiteFactor, CNKI Scholar, CNP Linker, COnnecting REpositories (CORE), De Gruyter, DeepDyve, Directory of Open Access scholarly Resources (ROAD), Directory of Research Journals Indexing (DRJI), EBSCO (Central & Eastern European Academic Source) (Login Required), EMBASE (Login Required), Global Health database (Login Required), Global Impact Factor (GIF), Google Scholar, HINARI Access to Research Initiative, Index Copernicus, InnoSpace Scientific Journal Impact Factor (SJIF), International Impact Factor Services (IIFS), JIFACTOR, JournalTOCs, Open Academic Journals Index (OAJI), Open Access Library (OALib), OVID EMBASE (Login Required), SCImago Journal & Country Rank (SJR), SciRew, Scopus (Login Required), Source Normalized Impact per Paper (SNIP), SouthEast European Science Advanced through Evaluation (SEESAmE), Summon™ Service (Login Required), The Knowledge Network, The Cochrane Library: Cochrane Database of Systematic Reviews, Universal Impact Factor, Wanfang Data, WorldCat.

Announcements

No announcements have been published.

More Announcements...

2016: OnlineFirst (OAMJMS)

Journal Help

NOTIFICATIONS
- View
- Subscribe

JOURNAL CONTENT
Search
Search Scope
All
Search

Browse
- By Issue
- By Author
- By Title
- By Identify Types
- Other Journals

FONT SIZE

KEYWORDS
Chronic period Ischemic stroke Kinesitherapy Macedonia Medical Publications Medical research Neurodevelopment treatment Obesity Republic of Macedonia Republic of Macedonia. adolescents breast cancer children congenital heart disease lipid profile medical science obesity questionnaire risk factors schizophrenia spirometry

CURRENT ISSUE

OA Maced J Med Sci electronic publication ahead of print,
published on January 22, 2016 as http://dx.doi.org/10.3889/oamjms.2016.021

ID Design 2012/DOOEL Skopje
Open Access Macedonian Journal of Medical Sciences
http://dx.doi.org/10.3889/oamjms.2016.021
eISSN: 1857-9655
Stomatology

Clinical Therapeutic Effects of the Application of Doxycycline in the Treatment of Periodontal Disease

Spiro Spasovski[1], Zlatanka Belazelkoska[2], Mirjana Popovska[2*], Aneta Atanasovska-Stojanovska[2], Vera Radojkova-Nikolovska[2], Ilijana Muratovska[2], Natasa Toseska-Spasova[2], Biljana Dzipunova[4], Bruno Nikolovski[3]

[1]PHO „Fjolla Medika". Skopje. Republic of Macedonia; [2]Faculty of Dentistry. Ss. Cyril and Methodius University of Skopje, 1000 Skopje. Republic of Macedonia; [3]PHO ETERNAdent. Skopje. Republic of Macedonia

Citation: [illegible]

Key words: [illegible]

Correspondence: [illegible]

Received: [illegible] **Revised:** [illegible]
Accepted: [illegible] **Online first:** [illegible]

Copyright: [illegible]

Competing Interests: The authors have declared that no competing interests exist

Abstract

OBJECTIVE: To compare the therapeutic effects of the application of doxycycline-full dose (100 mg) and sub-dose (20 mg) in the treatment of periodontal disease

MATERIAL AND METHODS: A total of 60 patients with periodontal disease were examined. Patients are divided into two groups: A) treated with antimicrobial dose of 100 mg doxycycline once daily for 30 days, and B) treated with 2 x 20 mg/day doxycycline, during 75 days. Among all patients a conservative treatment was carried out and ordinated the proper dose doxycycline in total dose during treatment from 3 gr. Index of dental plaque by Loe-Sillness, index of gingival inflammation and gingival bleeding by Cowell were followed

RESULTS: Values of dental plaque in relation first examination, 10th, 20th day, 1 month and 2.5 months, showed that after 2.5 months, average value (x = 0.83) of dental plaque in second group is slightly less than the value (x = 0.93) of dental plaque in the first group. The average value (x = 0.17) of gingival inflammation in second group is significantly less than the value (x = 0.50) of gingival inflammation in the first group. The average value (x = 0.97) of gingival bleeding in patients from the first group was significantly higher than value(x = 0.37) of gingival bleeding in the second group.

CONCLUSION: Patients whose therapy was helped by a sub-dose doxycycline demonstrated positive therapeutic effects on gingival inflammation and bleeding

Introduction

Treatment of periodontal disease includes removing of dental plaque and other irritating factors (conservative treatment) or performing surgical methods, which sometimes include the use of antibiotic therapy administered systemically or locally [1, 2]. The administration of local and systemic antibiotics, anti-inflammatory drugs, or sub-antimicrobial small doses of doxycycline applied as adjuvants have the opportunity to provide additional positive therapeutic effects [3, 4]. Sub-antimicrobial dose of doxycycline is 20 mg dose of the antibiotic applied twice daily in the treatment of periodontal disease. It is believed that a dose of 20 mg provides quite effective inhibition of enzymes, cytokines and osteoclasts than any antibiotic that would be applied in full or normal dose. On the other hand research studies have not spotted noticeable changes in the oral flora or bacterial flora in other organs in the individual's body because of which they identified as extremely recommended dosage which is a serious clinical utility when applied only in addition to periodontal pockets debridement [3]. For the clinician, this is particularly favorable moment, which enables broad applicability.

Well known fact is that periodontal disease is

Research (IJSR)
ISSN (Online): 2319-7064
www.ijsr.net | SJIF 2014: 5.611

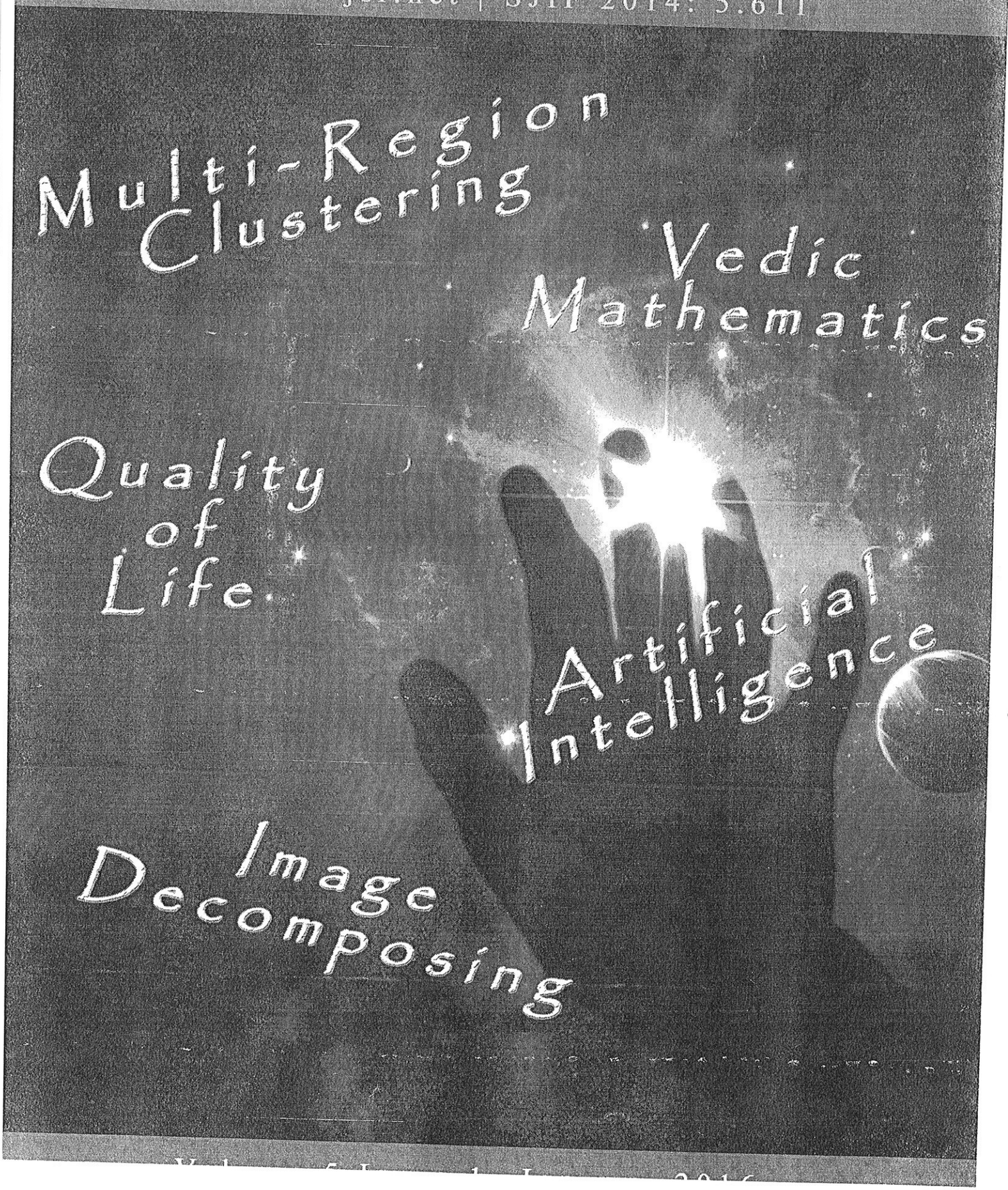

International Journal of Science and Research (IJSR)
ISSN (Online): 2319-7064
Index Copernicus Value (2013): 6.14 | Impact Factor (2014): 5.611

Etiopathogenetic Cellular Mechanisms in Oral Lichen Planus

Popovska M[1], Radojkova -Nikolovska V[2]., Minovska A[3]., Muratovska[4], Mijoska A[5]

[1, 2]University " St Ciril and Metodius" Faculty of Dentistry -Skopje, Republic of Macedonia

[3]University " Goce Delcev" Faculty of Medicine -Stip, Republic of Macedonia

[4, 5]University " St Ciril and Metodius" Faculty of Dentistry -Skopje, Republic of Macedonia

Abstract: *Objective: to follow the immune status in patients with oral lichen planus (OLP), by assessing the level of T and B lymphocytes in the blood. Material and method: 54 patients with OLP and 50 healthy people were examined. Experimental group was divided into three subgroups: reticular, erythema-exudative and bullous form. Both groups, control and experimental, were assessed for values of T and B lymphocytes in the blood in the Institute for Transfusion. Findings were statistically processed using the Student-t test. Results: In the phase of exacerbation in all three clinical forms of OLP, T and B cells in peripheral blood were increased, versus the control group (p<0.001). In the phase of remission in reticular, erythema-exudative and bullous form, slight decrease in the values of T and B cells was observed, but it was still above control values and with high significance (p<0.001), except for B lymphocytes in the reticular form where p <0.01. Conclusion: The increased values of T and B lymphocytes in the phase of exacerbation and remission, are explained with the chronicity of the process, which leads us to the conclusion that the immune system is reconstructed in terms of increased cell activity.*

Keywords: oral lichen planus, bullous, reticular, lymphocytes

1. Introduction

Modern science and medicine have clinical, histological, histochemical and other test methods, however the etiology of oral lichen planus is still relatively unknown. Recent literature supports the theory that the disease is associated with reactions that still cannot be completely defined, but began as a cellular immune respons.

Regezi comes to accurate information on the composition of the inflammatory infiltrate. The findings of the author are in favor of a general lack of plasma cells, suggesting the fact that the present cells in the infiltrates are likely T lymphocytes than B-cells [1].

Studies of serum lymphocytes and neutrophils in patients with oral lichen planus have proven the increase in CD4 and CD8 cell subpopulations, as well as decreasing CD4/CD8 cell ratio [2].

Sugerman in patients with oral lichen planus, found that the ratio of CD4 and $CD45RA^+$ T lymphocytes was significantly lower than in the control group [3]. Furthermore, spontaneous peripheral mononuclear cell proliferation was significantly lower in patients with non reticular form of the disease. The results of the phenotypic analysis of lymphocytes from peripheral blood indicated a decreased proportion of CD3 cells and an increased proportion of T-memory cells.

From the results obtained in this study association between oral lichen planus and T-cell subpopulations is apparent. It is said that the activation of mast cells by antigen specific cellular factors initiate a whole cascade of cellular reactions. Mast cells in sensitivised tissue release vasoactive amines that act on endothelial cells, resulting in increased vascular permeability [4].

Electron microscopy supports the concept that infiltrates in the lichen planus is a cellular immune response, which is dominated by T - lymphocytes. The absence of cells with negligible presence of widened endoplasmic reticulum is a proof that it is much more cellular than humoral immune response. However in biopsy material are found much more T-cells, although there is minimal synthesis of immunoglobulins.

So far, numerous studies have provided direct evidence for the central role of the cellular immune response in oral lichen planus. Serious support of this view is the study of Schiodt, which clinically and experimentally proved the presence of CD4 and CD8 cells [5]. His findings suggest that auto reactive CD4 cells may contribute to cytotoxicity, against the oral mucosa. Despite evidence of humoral autoimmunity and cellular hypersensitivity, however, the mechanism and evolution of the disease still remain unknown, if taken into account the fact that the initial phase of oral lichen planus, is clearly associated with leukocyte movement in normal and pathologically changed oral mucosa [6].

2. Objective

Based on previous data from the literature, we have set out the aim of this study: to follow the immune status in patients with oral lichen planus in the reticular, erythema-exudative and bullous form, in the phase of exacerbation and remission of disease, by assessing the level of T and B lymphocytes in serum.

Licensed Under Creative Commons Attribution CC BY

ISSN: 1309-100X

Journal of International Dental and Medical Research

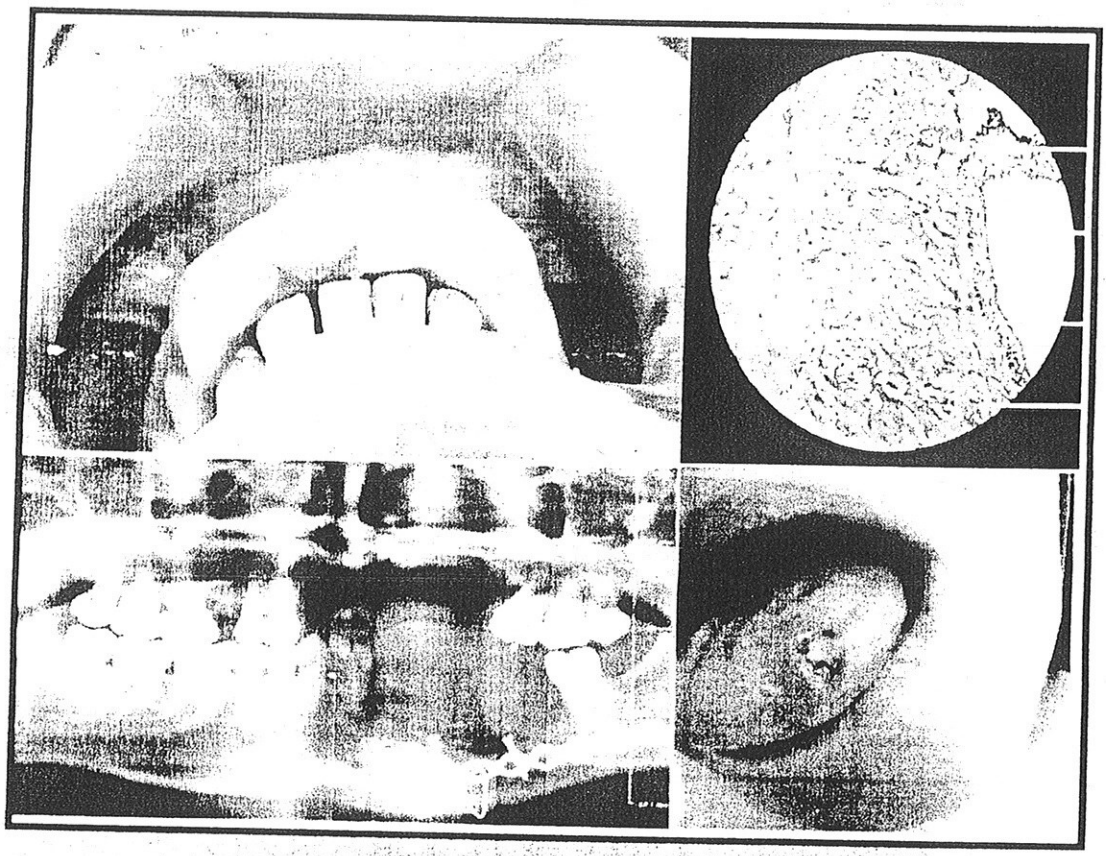

2016 - Vol. 9 - No. 1

http://www.ektodermaldisplazi.com/journal.htm

THE EFFECTS OF NBF GINGIVAL GEL IN THE TREATMENT OF RECURRENT ORAL ULCERS: CASE REPORT

Popovska Mirjana[1]*, Fidovski Jasmin[2], Radojkova- Nikolovska Vera[1], Dimova Cena[3], Popovska Lidija[1], Mijoska Aneta[1], Toseva-Spasovska Natasa[1], Dzipunova Biljana[1]

1. Professor, University Cyril and Methodius, Faculty of dentistry, Skopje, Republic of Macedonia.
2. MD, PHI "Fjola Medica", Republic of Macedonia.
3. Assoc. Professor, University Cyril and Methodius, Faculty of dentistry, Skopje, Republic of Macedonia.
4. Professor, University Goce Delcev Stip, Faculty of dentistry, Republic of Macedonia.
1. Professor, University Cyril and Methodius, Faculty of dentistry, Skopje, Republic of Macedonia.
1. Assoc. Professor, University Cyril and Methodius, Faculty of dentistry, Skopje, Republic of Macedonia.
1. Assoc. Prof. University Ss. Cyril and Methodius, Faculty of dentistry, Skopje, Republic of Macedonia.
1. Assoc. Prof. University Ss. Cyril and Methodius, Faculty of dentistry, Skopje, Republic of Macedonia.

[illegible] that during the last three years, he had sores appeared on the lips, tongue and [illegible] with severe pain emphasized while taking food, inability to speak [illegible] maintain daily oral hygiene. Clinical examination of oral mucosa showed [illegible] lesions, two on buccal mucosa and one on the tongue. The aphthae had an [illegible] irregular edges, steep bloody sides and milky white [illegible] was presented around ulcerated area. The patient applied topically, NBF [illegible] three times daily after meals, prior rinsing with 12% Chlorhexidine gluconate. [illegible] was recorded after 7 days of treatment, and after two weeks of gel application [illegible] was noted. There was withdrawal of infiltration and edema, mild [illegible] with present erythematous base. The pain was moderate, but [illegible] was still present. The erythematous area was [illegible] and epithelization was visibly advanced after the second week. The [illegible] was decreased, with depth reduced two times. After the third week [illegible] redness was still present. Complete withdrew happened after week [illegible]

Case report, Review (J Int Dent Med Res 2016; 9: (1), pp: 81-85)

Keywords: Recurrent aphthae's ulcer, therapy, topical treatment, NBF gingival gel.

Received date: 10 March 2016 Accept date: 28 March 2016

Introduction

Aphtae are ulcerated lesions that look like an erosion, disrupting the epithelial continuity, located in the connective tissue, and appearing on mucosal surfaces [1,2]. Recurrent aphthae lesions are small, round or oval ulcers with erythematous halo and yellow or dirty white covering [2-4], with the exception of Sutton sores which are large, irregular and infiltrated.

The reasons for their appearance are: allergy, stress, hematologic, gastrointestinal, rheumatic diseases, infectious agents, nutritional deficiencies, genetic predisposition, hormones etc [5-7].

These factors have direct or indirect impact on the balance of oxidative and antioxidant system. The creation and release of free radicals can be accelerated, and toxic reactions may occur when this balance is disrupted [7,8]. It is possible link between the level of free radicals and recurrent oral lesions [9], because the role of antioxidants is important in maintaining oral health [10]. The treatment of recurrent aphthous ulcers is mainly local (if there

Corresponding author:
Mirjana Popovska,
Majka Teraza bb 1000 Skopje, Republic of Macedonia,
Tel: +389 2 3299-038
E-mail: popovskam2002@yahoo.com

BANTAO
Journal

Journal of the Balkan Cities Association of Nephrology, Dialysis, Transplantation and Artificial Organs

Home
Aims and scops
Current issue
Instructions for authors
Subscription

Current issue

2015 Volume 13 issue 1

Archive

search

search for articles in title, author or page

2015	Volume 13 issue 1		
2014	Volume 12 issue 1	2014	Volume 12 issue 2
2013	Volume 11 issue 1	2013	Volume 11 issue 2
2013	Volume 11 Supplement 1 (Abstracts)		
2012	Volume 10 issue 1	2012	Volume 10 issue 2
2011	Volume 9 issue 2		
2011	Volume 9 issue Suppl. 1	2011	Volume 9 issue 1
2010	Volume 8 issue 1	2010	Volume 8 issue 2
2009	Volume 7 issue 1	2009	Volume 7 issue 2
2009	Volume 7 Supplement 1		
2008	Volume 6 issue 1	2008	Volume 6 issue 2
2007	Volume 5 issue 1	2007	Volume 5 issue 2
2006	Volume 4 issue 1	2006	Volume 4 issue 2
2005	Volume 3 issue 1	2005	Volume 3 issue 2

BANTAO Journal 2014; 12(1): 95-100

BJ
BANTAO Journal

Original article

Oral and Salivary Changes in Patients with Chronic Kidney Disease

Ana Belazelkovska[1], Mirjana Popovska[2], Goce Spasovski[3], Jelka Masin-Spasovska[3], Svetlana Cekovska[4], Aneta Atanasovska-Stojanovska[2], Kristina Mitic[2] and Vera Radojkova-Nikolovska[2]

[1]Faculty of Dentistry, European University, Skopje, [2]Department of Oral Pathology and Periodontology, Faculty of Dental Medicine, University "Ss Cyril and Methodius", Skopje, [3]Department of Nephrology, [4]Department of Medical and Experimental Biochemistry, University "Ss Cyril and Methodius", Skopje, Republic of Macedonia

Abstract

Introduction. Kidney disease is associated with many abnormalities in the oral health status as well as with alterations in salivary flow and composition. The aim of this study was to evaluate and to correlate oral clinical findings, salivary flow (SF) and salivary pH values in patients with chronic kidney disease (CKD) not yet on hemodyalisis treatment, those undergoing hemodialysis and in kidney transplant recipients.
Methods. In a cross-sectional study 90 patients were included. The cohort was composed of three groups: 30 patients with CKD (serum creatinine values under 120 μmol/L-group 1), 30 patients with CKD on hemodialysis (group 2) and 30 kidney transplanted patients (group 3). The control group consisted of 20 healthy individuals. Oral symptoms, signs and lesions: salivary volume, salivary pH and SF of stimulated and unstimulated saliva were evaluated.
Results. Among patients with CKD without dialysis treatment inverse relationship was found between uremic fetor, unpleasant taste and unstimulated SF and also between xerostomia and stimulated SF. Negative correlation between thirst and unstimulated salivary flow was found in both groups, patients with CKD on dialysis and kidney transplant group. Furthermore, in kidney-transplant patients a negative correlation was found between petechiae and SF, while in group of patients with CKD on hemodialysis the same negative correlation was registered between uremic fetor and stimulated SF.
Conclusions. Salivary flow was significantly lower in hemodialysis patients, while the highest was in the kidney-transplant recipients accompanied with improvement in the other oral clinical findings observed in our study.

Key words: hemodialysis, kidney transplantation, oral findings, salivary flow

Introduction

Patients with chronic kidney disease (CKD) often present systemic complications such as anemia, coagulation and platelet function disorders [1]. Some of them manifest oral symptoms and signs [2]. Oral symptoms may be more or less prevalent in the oral mucosa [3,4]. It has been proven that approximately 90% of the patients with CKD have soft tissue changes [5]. Besides changes in the soft tissue, in these patients there is an increased risk of caries which is considered to be a multifactorial disease. Several studies have reported the connection of the salivary flow with periodontal, dental and oral status in CKD patients [6,7]. It has been also reported that in CKD patients saliva has important protective properties, participating in the maintenance of oral mucosa and hard tissues integrity, that is in the physiological balance within normal condition. Any deviation may influence the condition of the tissues in the oral cavity [8]. Salivary buffer capacity is an important parameter in maintaining pH of saliva, thereby reflecting on the integrity of soft and hard tissue in the oral cavity [9-11].
According to Bots *et al.* [6] any disorder which influences on the established equilibrium of all components in the oral cavity leads to a reduction in salivary flow, which may cause symptoms and signs of xerostomia and atrophic changes on the oral mucosa. It is considered that determination of some biomarkers in saliva can be effective alternative method for monitoring the efficacy of the treatment with dialysis in CKD patients [12]. In that context Blicharz *et al.* [12] believe that saliva sample represents a revolution in diagnostic and therapeutic monitoring strategies in CKD patients and those suffering from other chronic diseases.
Considering these facts the aim of our study was to find the association between salivary flow and oral clinical findings in patients with chronic kidney disease.

Correspondence to: Ana Belazelkovska, Faculty of Dentistry, European University, Mito Hadzivasilev-Jasmin bb, 1000 Skopje, R. Macedonia. Phone: +389 70 212 513; E-mail: abelazelkovska@yahoo.com

Volume 20 · No. 2 · 2013

Balkan Journal of DENTAL MEDICINE

Successor of the BALKAN JOURNAL OF STOMATOLOGY

DE GRUYTER OPEN

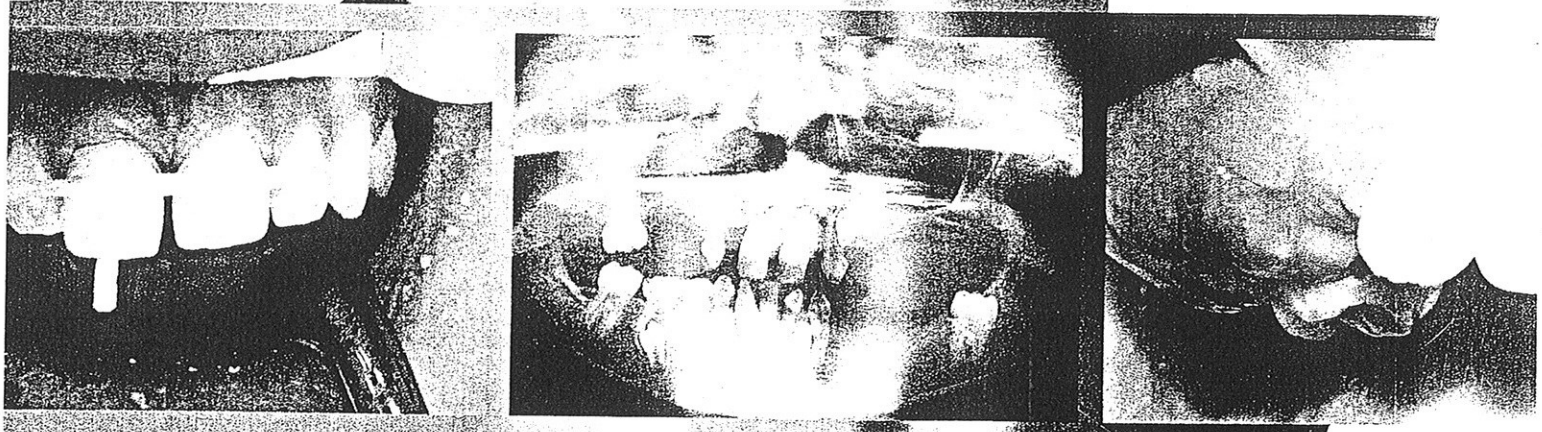

Official Journal of the Balkan Stomatological Society

ISSN 2335-0

DE GRUYTER
OPEN

10.1515/bjdm-2016-0009

BALKAN JOURNAL OF DENTAL MEDICINE

BaSS

ISSN 2335-0245

Osteoradionecrosis of the Mandible: A Case Report

SUMMARY

Osteoradionecrosis (ORN) of the jaws is a serious complication of radiotherapy of head and neck malignancies. Different assumptions about its occurring, risk factors and possible therapeutical modalities exist, but the clinical outcome of such patients is still not on the desired level. This article presents a clinical case of ORN of the mandible, occurring with exposed and infected bone, necrotic process that extended through all the mandible body, as well as cutaneous fistula. The first site of ORN was detected 2 years after radiotherapy for oral cancer, with the second one detected 3 and a half years after radiotherapy. In both, the reason for exposing the bone was local trauma due to tooth extraction. Due to the stage of the condition, a decision for surgical treatment accompanied with antibiotics was made.

It is very important and critical for irradiated patients and patients with osteoradionecrosis to perform appropriate oral hygiene and frequent dental checks. Establishing protocols for prevention and treatment, but involving some new strategies regarding to this condition, are strongly recommended.

Keywords: Osteoradionecrosis; Mandible; Radiotherapy

Danica Popovik-Monevska[1], Ilijana Muratovska[2], Mirjana Popovska[3], Suzana Dvojakovska[1], Filip Koneski[1]

Ss. Cyril and Methodius University of Skopje, Faculty of Dentistry, Skopje, FYROM
[1]Department for Maxillofacial Surgery
[2]Department for Restorative Dentistry and Endodontics
[3]Department for Periodontics and Oral Medicine

CASE REPORT (CR)
Balk J Dent Med, 2016; 20:54-59

Introduction

Osteoradionecrosis (ORN) of the jaws is a serious complication of radiotherapy of head and neck malignancies. It is clinically defined as exposed and necrotic bone associated with ulcerated or necrotic surrounding soft tissue, which persists for more than 3 months in an area that had been previously irradiated (not caused by tumour recurrence)[1,2]. The radiation dose between 60 and 72 Grays has an effect on the endothelial linings of the blood vessels, causing vasculitis and endarteritis, which lead to ischemia and hypoxia due to hypovascularity[3,4]. Hypocellular and fibroatrophic component is suggested by some authors as well[5]. ORN occurs predominantly in the lower jaw, commonly in the buccal cortices of lateral site[6,7]. The most important inducing factor is surgical trauma, commonly a dental extraction. Other trauma, mechanical injuries, poor dental status etc. can induce the necrosis as well[1-10]. Sometimes, in less than 10%, ORN occurs spontaneously[11]. Some systemic and chronic diseases (diabetes, cardiovascular diseases) and bad habits (smoking, alcohol consuming) can worsen the condition[6,9,10]. The wound that appear after the trauma is failing to heal, so tissue breakdown and necrosis occur.

The most common clinical signs and symptoms of ORN are: pain, swelling, bone exposing, secondary infection, fistula occurring and bone loss. If not treated, the condition usually worsens. Depending on clinical presentation, ORN can be classified in 3 classes (stages)[12]: First stage includes patients with ORN limited to dento-alveolar segment; second stage of ORN is limited to dento-alveolar bone or the mandible, not crossing the mandibular canal; third stage includes the most complicated cases in whom ORN involves the mandible above the mandibular canal or it is presented with pathological fracture or skin fistula.

The prevalence of ORN in those with cancer of the head and neck is around 7.4% after conventional radiotherapy, 5.1% after intensity-modulated radiotherapy (IMRT), and 6.8% after chemo-radiotherapy[14].

Unauthenticated
Download Date | 1/31/17 11:14 AM

Volume 44, Supplement 1 24 September 2011 ISSN 0928-0987

ELSEVIER

European Journal of PHARMACEUTICAL SCIENCES

Official Journal of the
EUROPEAN FEDERATION FOR PHARMACEUTICAL SCIENCES

SUPPLEMENT

4th BBBB-Bled International Conference on Pharmaceutical Sciences
New Trends in Drug Discovery, Delivery Systems and Laboratory Diagnostics
29th September – 1st October, 2011
Bled, Slovenia

OPTIMIZATION OF A HPLC METHOD FOR DETERMINATION OF BETAMETHASONE DIPROPIONATE IN GINGIVAL CREVICULAR FLUID

L. Bogdanovska[1,*], R. Petkovska[1], M. Popovska[2], A. Dimitrovska[1]

[1] University "Ss Cyril and Methodius", Faculty of Pharmacy, Vodnjanska 17, 1000 Skopje, Macedonia; [2] University "Ss Cyril and Methodius", Faculty of Dentistry, Vodnjanska 16, 1000 Skopje, Macedonia

INTRODUCTION

Scaling and root planning (SRP) are the bases of non-surgical therapy in the treatment of periodontitis. Betamethasone dipropionate is often used in dentistry, after the nonsurgical, conventional treatment for periodontitis, because of its topical anti-inflammatory and immunosuppressive actions although the precise mechanism for its activity is unknown. It has greater antiinflammatory potential in relation to other topical corticosteroids (1). Gingival crevicular fluid (GCF) is a serum transudate or inflammatory exudate which plays very important role in the oral defence mechanism (2). Drugs that are distributed in gingival fluid may therefore be very important for the treatment of periodontal disease (3).

The aim of our study was to optimise a HPLC method for determination of betamethasone dipropionate in gingival crevicular fluid after topical application of betamethasone dipropionate 0.5 mg/g cream on the inflamed gingiva.

MATERIALS AND METHODS

Materials

Methanol (HPLC-grade) was supplied by Merck (Darmstadt, Germany) and analytical grade monobasic potassium phosphate was purchased from Fluka. Betamethasone dipropionate and aclo- methasone dipropionate (used as an internal standard) reference standards were used to prepare stock standard solutions.

Whatmann 3MM Chromatography paper strips 2x5mm (Whatmann Lab Sales Ltd., Maidstone, Kent,UK) were used for GCF collection.

Preparation standard solutions

Standard solutions were prepared each day in concentrations of 0.1, 0.25, 0.5, 0.75, 1 and 2 µg/ml each containing 2 µg/ml aclomethasone as an internal standard, using mobile phase as diluting agent.

Collection of Gingival Crevicular Fluid

GCF was collected from ten volunteers 21 to 65 years old, suffering from moderate periodontitits. The applied volume of the cream was 0.1 ml to each volunteer and specimens were taken 15 minutes after treatment.

GCF samples were collected using Whatmann paper strips. The paper strips were inserted into the deepest periodontal pockets (PD≥4 mm) until minimal resistance was felt and were left there for 30 s (4). Average volume of GCF collected on the paper strips was 0.4 µL. Samples containing blood were not included for analysis. All the samples were frozen at - 20°C until analysis.

Extraction procedure

Samples were extracted using MeOH:H_2O (70:30, v/v) mixture. The final extract volume was 500 µL. Aclomethasone internal standard (10 µL 100 µg/ml solution) was added to each extract.

Chromatography

The HPLC analysis was conducted on Agilent 1100 series equipped with UV Diode Array Detector. The chromatographic separation was performed on Purospher STAR RP 18-e 120 Å, 150 x 4.6 mm, 5µm using LiChroCART® 4-4 guard column at 25 °C. The mobile phase was methanol 0.04M KH_2PO_4 (70:30, v/v) with flow rate of 1.3 ml min^{-1}. The injection volume was 100 µl. UV detection was performed at 245 nm. The run time was 14 min.

RESULTS AND DISCUSSION

Validation

The HPLC method was validated according to EMEA Guideline for the validation of bioanalytical methods (5). The retention times for aclomethasone (IS) and betamethasone dipropionate were 6.5 and 11 min, respectively.

The method was linear in the concentration range from 0.1-2 µg/ml (y=0.513x-0.003, R^2=0.997). Recovery of extraction in human GCF was calculated by comparing the peak area ratio from an extracted spiked sample with the peak area of blank GCF containing the same amount of drug. The mean recovery was 98.75%. The precision and accuracy were determined at four concentration levels, 0.1, 0.25, 1, 1.75 µg/ml (Table 1).

Table 1: Within-run and between-run accuracy and precision for betamethasone in GCF

Added (µg/ml)	Determined (µg/ml)	CV (%)	Accuracy (%)
With-in run accuracy and precision			
0.10	0.11	3.51%	109,06 %
0.25	0.25	4.00%	99,71%
1,00	0.97	2.22%	96.67%
1.75	1.73	4.53%	98.77%
Between run accuracy and precision			
0.10	0.10	4.38%	103.45%
0.25	0.25	3.25%	99.11%
1.00	0.96	2.00%	96.89%
1.75	1.77	5.71%	100.97%

The selectivity of the method was demonstrated as the resolution of the beta- methasone dippropionate peak from other peaks and absence of interfering peaks (Fig.2).

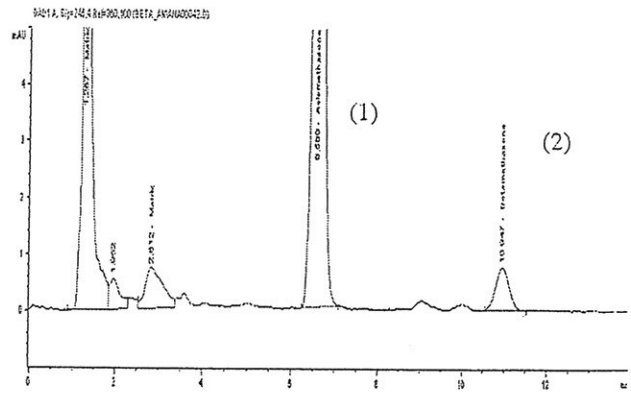

Fig. 2: Representative chromatogram of GCF sample. Peaks: (1)-aclomethasone dipropionate (internal standard, 2µg/ml; (2)-betamethasone dipropionate, 0.15µg/ml

Analysis of betamethasone dipropionate in human GCF

Results from patients show that betamethasone dipropionate applied as a cream penetrates well into human crevicular fluid as evidenced by the levels obtained (Table 2).

This may have implications in the basis of non-surgical therapy for periodontitis.

Table 2: Concentration of betamethasone in patient samples

Patient	Concentration applied (µg/ml)	Concentration determined (µg/ml)	%
No.1	0.25	0.2375	95.00
No.2	0.25	0.2369	94.76
No.3	0.25	0.2198	87.92
No.4	0.25	0.2223	88.90
No.5	0.25	0.2298	91.92
No.6	0.25	0.2350	94.00
No.7	0.25	0.2284	91.36
No.8	0.25	0.2151	86.04
No.9	0.25	0.2173	86.92
No.10	0.25	0.2138	85.52

CONCLUSION

The data presented in this study indicate that the HPLC method used for the determination of betamethasone dipropionate in human crevicular fluid samples showed parameters of precision, accuracy, linearity, and specificity in the limits of validation criteria. Additionally the recovery of extraction in human GCF was satisfactory.

The HPLC method are therefore suitable and applicable for the analysis of betamethasone dipropionate in human crevicular fluid.

REFERENCES

1. Fachin EVF, Zaki AE. Histology and lysosomal cytochemistry of the postsurgicaly inflamed dental pulp after topical application of steroids.I.Histological study. J.Endod. 1991 ; 17(9) : 457-60
2. Kinney,S.J., Rameseler,A.C, Glanobille V. W. Oral Fluid-Based Biomarkers of alveolar bone loss in periodontitis. Ann.N.Y. Acad.Sci.1098: (2007); 230-251
3. Babinchak J.T. Oral ciprofloxacin therapy for prosthetic valve endocarditis due to Actinobacillus actinomycetemcomitans. Clin.Infect.Dis. 1995; 21(6) : 1517-1518
4. Lamster B.I, Ahlo K.J. Analysis of gingival crevicular fluid as applied to the diagnosis of oral and systemic diseases.Ann.NY.Acad.Sci. 2007;1098:216-229
5. EMEA. Guideline on validation of bioanalytical methods. EMEA/CHMP/EWP/192217/2009

A NEW METHOD FOR MONITORING OXIDATIVE STRESS MARKERS IN EXHALED BREATH CONDENSATE

K. Syslová[1,*], P. Kačer[1], M. Kuzma[2], Š. Vlčková[3], Z. Fenclová[3], J. Lebedová[3], D. Pelclová[3]

[1] Institute of Chemical Technology, Technická 5, 166 28 Prague 6, Czech Republic; [2] Institute of Microbiology, Vídeňská 1083, 142 20 Prague 4, Czech Republic; [3] Department of Occupational Medicine, 1st Medical Faculty, Charles University, Na Bojišti 1, 120 00 Prague 2, Czech Republic.

INTRODUCTION

Oxidative stress can be defined as the body imbalance between production of reactive oxygen species (ROS) and biological system ability to readily detoxify the reactive intermediates or easily repair the resulting damage. ROS generated close to cell membranes oxidize membrane phospholipids (membrane lipid peroxidation), which can be further transformed in a chain reaction. Endoge-nously generated aldehydic lipid peroxi-dation products are malondialdehyde, α,β-unsaturated aldehydes (mainly 4-hydroxynonenal and 4-hydroxyhexenal) and saturated aldehydes (hexanal, heptanal and nonanal). Aldehydes are formed by lipid peroxidation of ω-6 (arachidonic acid, linoleic acid) and ω-3 (oleic acid) polyunsaturated fatty acids. The aldehydes (biomarkers) quantification in various body fluids (exhaled breath condensate, plasma and urine) represent an interesting tool for oxidative stress induceddiseases diagnostics.

MATERIALS AND METHODS

The work presents a new method for the determination of aldehyde biomrkers in body fluids based on the LC-ESI/MS/MS. Malonodialdehyde, 4-hydro-xynonenal, and saturated aldehydes (n-C6 to C13 aldehydes) were quantified after derivatization with Girard's reagent T. LC-ESI-MS/MS operated in neutral loss (NL) mode was used for its exceptionally high degree of selectivity and sensitivity.

RESULTS AND DISCUSSION

It was developed very sensitive and easy-to-use protocol for high throughput analysis of carbonyl compounds in the EBC. Optimized electrospray ionization conditions established the limits of detection at 12 pg/ml and 16 pg/ml of the EBC for the most prominent oxidative stress markers MDA, and 4-HNE respectively. The validation results demonstrated that the LC–MS/MS method is precise (≥ 91.3%), accurate (≥ 89.3%) and selective and can be used for the determination of carbonyl compounds in the EBC.

CONCLUSIONS

The developed method enabled unequivocal parallel determination of several oxidative-stress biomarkers at the only one analysis run. The method was tested on real clinical samples collected from patients with different oxidative stress induced disorders (silicosis, asbestosis) and compared to the control group of healthy subjects.

ACKNOWLEDGEMENT

The work was supported by the Ministry of Health of the Czech Republic (Grant NS 10298-3/2009) and Grant Agency of the Czech Republic (Grant GA CR 203/08/H032).

SYNTHESIS AND ANTIMICROBIAL ACTIVITY OF NEW PYRAZOLINE DERIVATIVES

A. Özdemir[1,*], G. Turan-Zitouni[1], Z. A. Kaplancıklı[1], M. D. Altıntop[1], F. Demirci[2]

[1] Anadolu University, Faculty of Pharmacy, Department of Pharmaceutical Chemistry, 26470, Eskisehir, Turkey; [2] Anadolu University, Faculty of Pharmacy, Department of Pharmacognosy, 26470, Eskisehir, Turkey.

INTRODUCTION

In recent decades, problems of multidrug resistant micro-organisms have reached an alarming level in the world. Resistance to a number of antimicrobial agents (β-lactam antibiotics, macrolides, quinolones, and vancomycin) among a variety of clinically significant species of bacteria is becoming increasingly major global problem. They pose a serious challenge to the scientific community hence emphasis has been laid on the development of new antimicrobial agents. Pyrazolines are five-membered heterocyclic compounds containing two nearby nitrogen atom on their chemical scaffold. Several pyrazoline derivatives possess important pharmacological activities including antimicrobial activity (1) and therefore they are useful materials in drug research. In addition, several 1,3,4-oxadiazole derivatives were reported to exhibit good antimicrobial activity (2). In view of the above observations, we have designed and synthesized new 2-pyrazoline derivatives, bearing oxadiazole, thienyl and phenyl functionality in the same molecule, as potential antimicrobial agents.

MATERIALS AND METHODS

Chemistry

All chemicals were obtained from Aldrich Chemical Co. All melting points (m.p.) were determined by Gallenkamp apparatus and are uncorrected.

Journal of Macedonian Association of Physiologist and Anthropologist

Physioacta

Vol. 7 - No. 2
2013

UDC: 616.31-006.6-085.849

ORAL AND DENTAL STATUS IN PATIENTS WITH PLANOCELLULAR CARCINOMA ORIGINATING FROM THE ORAL CAVITY, OROPHARYNX OR HYPOPHARINX DURING RADIOTHERAPY

Popovska M [1], Krstevska V [2], Krstevska O [1], Atanasovska-Stojanovska A[1], Radojkova-Nikolovska V[1], Minovska A[3], Goga Cmeka V[4], Muratovska I[1], Mitic K [1], Belazelkoska A [1], Kapupevska B[1], Pandilova M[1], Strezovska S[5]

[1] Univerzitet " Sv. Kiril i Metodij", Stomatoloski fakultet -Skopje, JZU Stomatoloski klinicki centar-Skopje
[2] JZU Univerzitetska klinika za radioterapija i onkologija - Skopje
[3] Univerzitet " Goce Delcev" Stomatoloski fakultet - Stip
[4] Stomatoloski fakultet-Pristina
[5] PZU"Idadija" Skopje

Abstract

Aim: To evaluate oral and dental changes in the oral cavity during radiotherapy course, depending of the applied radiation dose in patients with planocellular carcinoma that originates from the oral cavity, oropharynx, or hypopharynx.

Material and methods: In order to realize this goal, for three months in 2007, we followed up 40 patients of both sexes, aged 40 to 70 years. Patients were divided into four groups according to the time when was conducted the analysis of the radiation-induced reactions in the oral cavity. The first group of patients were examined after the first week of irradiation, when the accomplished dose of radiation was10 Grey(Gy). The second group of patients was examined during the second week after the start of radiotherapy, when the achieved dose was between 10 and 20 Gy. The third group was consisted of patients examined in the third and fourth week of treatment when the achieved dose by radiotherapy was between 22 and 40 Gy, and the fourth group was consisted of those patients in whom the analysis of radiation effects was performed in the fourth week of the radiotherapy when the radiation exceeded 40 Gy.

From the subjective symptoms were followed: pain, dry mouth and difficulties in swallowing. The objective symptoms that we have monitored were: appearance of erythema, erosions, ulcerations and loss of tongue papillae. Dental examination was carried out by evaluating the dental status noting demineralization, caries lesions and atypical fractures of enamel.

Results: After accomplishing a dose of 10 Gy, there was not recorded existence of pain in any patient. Mild pain was recorded in 5 patients (12.5%), after achieved dose of 12 to 20 Gy and in 13 patients (32.5%) with radiation dose of 22 to 40 Gy. Moderate pain was observed in 10 patients (25.0%) at achieved radiation dose of 22 to 40 Gy and severe pain in 12 patients (30.0%) with achieved radiation dose above 40 Gy. Erythema, erosion, ulceration and loss of tongue papillae in examined patients have showed a proportional increase with the increase of the applied radiation dose. Therefore, at achieved radiation dose more than40 Gy, erythema was present in 77.5% of the patients, 72,.5% patients had erosions, ulcerations and loss of tongue papillae were noted in 47.5% and 65.0% of the patients respectively. Most common dental changes in patients were atypical caries lesions present in almost 90.0%, with a predominance of 50.0% in

Romanian Journal of Oral Rehabilitation

Vol. 5, No. 2, April – June 2013

Editor in Chief
Norina Consuela Forna, Iaşi, Romania

Vice-Editor
Viorel Păun, Bucharest, Romania

Senior Associate Editors
Pierre Lafforgue, Paris, France
Sami Sandhaus, Lausanne, Switzerland
Robert Sader, Frankfurt, Germany
Zhimon Jacobson, Boston, USA

Editorial Board
Corneliu Amariei, Constanţa, Romania
Vasile Astărăstoae, Iaşi, Romania
Sorin Andrian, Iaşi, Romania
Grigore Băciuţ, Cluj Napoca, Romania
Constantin Bălăceanu – Stolnici, Bucharest, Romania
Marc Bolla, Nice, France
Dorin Bratu, Timişoara, Romania
Alexandru Bucur, Bucharest, Romania
Eugen Carasevici, Iaşi, Romania
Radu Septimiu Câmpean, Cluj Napoca, Romania
Costin Cernescu, Bucharest, Romania
Yves Commissionat, Paris, France
Marysette Folliguet, Paris, France
Cristina Glavce, Bucharest, Romania
Emilian Hutu, Bucharest, Romania
Constantin Ionescu – Tîrgovişte, Bucharest, Romania
Michel Jourde, Paris, France
Ion Lupan, Chişinău, Rep. of Moldavia
Veronica Mercuţ, Craiova, Romania
Patrick Missika, Paris, France
Ostin Costin Mungiu, Iaşi, Romania
Ady Palti, Kraichtal, Germany
Mihaela Păuna, Bucharest, Romania
Phillipe Pirnay, Paris, France
Constantin Popa, Bucharest, Romania
Sorin Popşor, Tg. Mureş, Romania
Dorin Ruse, Vancouver, Canada
Valeriu Rusu, Iaşi, Romania
Adrian Streinu-Cercel, Bucharest, Romania
Dragoş Stanciu, Bucharest, Romania
Mircea Suciu, Tg. Mureş, Romania
Alin Şerbănescu, Cluj Napoca, Romania
Monica Tatarciuc, Iaşi, Romania

General Secretary
Magda Ecaterina Antohe, Iaşi, Romania
Oana Ţănculescu, Iaşi, Romania

Legislation Committee
Delia Barbu, Bucharest, Romania

DEMIURG Publishing House

Romanian Journal of Oral Rehabilitation
Vol. 5, No. 3, July - September 2013

CONVENTIONAL VERSUS LASER-ASSISTED THERAPY WITH AGGRESSIVE PERIODONTITIS

Mirjana Popovska[1*], Milco Ristoski[2], Aneta Atanasovska-Stojanovska[3], A. Minovska[4], V. Radojkova-Nikolovska[1], Biljana Kapusevska[5], Kristina Mitic[1], Lindita Zendeli-Bedzeti[3], Spiro Spasovski[1]

[1] University "Ss Cyril and Methodius", Skopje, Republic of Macedonia, Faculty of Dental Medicine, Department of Oral Pathology and Periodontology

[2] University "Ss Cyril and Methodius", Skopje, Republic of Macedonia, Faculty of Medicine, Institute for Pathologic Anatomy

[3] University Dental Clinical Center "St. Pantelejmon", Skopje, Republic of Macedonia, Clinic for Oral Pathology and Periodontology

[4] University "Goce Delcev", Stip, Republic of Macedonia, Clinic for Oral Pathology and Periodontology

[5] University "Ss Cyril and Methodius", Skopje, Republic of Macedonia, Faculty of Dental Medicine, Department of Prosthetics Dentistry

*Corresponding author: Mirjana Popovska, Professor, PhD
University "Ss Cyril and Methodius",
Skopje, Republic of Macedonia
e-mail: popovskam2002@yahoo.com, phone: +389 2 3299-038

ABSTRACT

Aim of the study To evaluate tissue response in aggressive periodontitis (AgP) after conventional and conventional supplemented with laser-assisted therapy. **Material and methods** This study included 50 subjects with AgP, aged 10 -24 year, which were divided into two subgroups. Firs subgroup 25 subjects treated only with conventional therapy (CP) and second subgroup of 25 subjects which were treated with laser assisted therapy (CP-LA). Low-level diode laser (630-670 nm, 1,875 J/cm) was applied, each sextant for 4 minutes, Scorpion C-405 7A (Optica Laser, Sofia, Bulgaria). The control group consisted of 20 individuals, aged 13-24 years, without signs of periodontal disease. Gingival tissue biopsies were obtained from the controls and from the study group before and after conventional and with laser assisted treatment. Tissue specimens were embedded in paraffin and cryostat procedures were performed. **Results** Gingival tissue specimens from study group compared to controls showed dense infiltrate. Subject with AgP revealed heterogeneous inflammatory infiltrate with dense and less dense areas. Almost equal values from quantitative measurements of connective tissue inflammatory infiltrate were obtained. Mean values for study group before treatment were 39,18± 14,02. For the first subgroup mean values ranged 35,92± 14,02, and mean values for the second subgroup were 35.01 ± 13.25. Qualitative analysis in study group after conventional without and with lasser assistance revealed insignificant values of mononuclear and plasma cells and Russell bodies. **Conclusions** Laser application did not induce quantitaive nor qualitative changes in the gingival tissue inflammatory infiltrate in study group. On the basis of our findings we suggest that low level laser assisted therapy does not proof to be efficient in the treatment of aggressive periodontitis.

Key words: Aggressive periodontitis, Low-level diode laser, Gingiva, Periodontal therapy